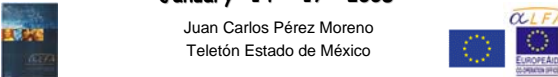


**Second Course "Motion Analysis and clinics:
why to set up a Motion Analysis Lab ?"**
- *Clinical cases presentation* -


TRAMA Project
January 14 - 17th 2008
Juan Carlos Pérez Moreno
Teletón Estado de México



Clinical case presentation

- Previous treatment: Knee osteotomy surgery (02-2003). Genu valgus alignment and tibial bone distractor –Orthopix (06-2003).
- Rehabilitation program: Exercise program, cuadriceps strength training and orthotic devices.
- Range of motion exercises to preserving joint function


Course "Motion Analysis and clinics: why to set up a Motion Analysis Lab ?"
- *Clinical cases presentation* - TRAMA Project – January 14 – 17th 2008



Clinical case presentation

- General data: Male, 15 years old, with diagnoses of Morquio syndrome (MPS IV/A).
- History: Perinatal history without problems, since year-old noticed the chest deformity and growth delay, evaluated by genetics becoming the diagnosis of Morquio syndrome A.

Course "Motion Analysis and clinics: why to set up a Motion Analysis Lab ?"
- *Clinical cases presentation* - TRAMA Project – January 14 – 17th 2008



Clinical case presentation



Course "Motion Analysis and clinics: why to set up a Motion Analysis Lab ?"
 - Clinical cases presentation - TRAMA Project – January 14 – 17th 2008

Clinical case presentation

- Physical assessment: Normal hip ROM, knee extension: -20°/-5°; hamstring contracture 25°/20°; triceps contracture: 10°/10°; genu valgum 40°/10° and talus valgus 10°/20°.

Course "Motion Analysis and clinics: why to set up a Motion Analysis Lab ?"
 - Clinical cases presentation - TRAMA Project – January 14 – 17th 2008

Clinical case presentation

- Clinical evaluation: Normal brain functions, facial bone dysostosis, thickening of the alae nasi, lips and tongue, cardiac involvement, early bone involvement with dysostosis, thickening of the ribs, dorsolumbar kyphosis, progressive skeletal dysplasia and long bones are short with wide shafts.

Course "Motion Analysis and clinics: why to set up a Motion Analysis Lab ?"
 - Clinical cases presentation - TRAMA Project – January 14 – 17th 2008

Clinical case presentation

Quantitative 3D evaluation

Course "Motion Analysis and clinics: why to set up a Motion Analysis Lab ?"
 - Clinical cases presentation - TRAMA Project – January 14 – 17th 2008

Clinical case presentation




Quantitative 3D evaluation

Course "Motion Analysis and clinics: why to set up a Motion Analysis Lab ?"
 - Clinical cases presentation - TRAMA Project – January 14 – 17th 2008

Clinical case presentation


Quantitative 3D evaluation




Course "Motion Analysis and clinics: why to set up a Motion Analysis Lab ?"
 - Clinical cases presentation - TRAMA Project – January 14 – 17th 2008

 **Clinical case presentation**  

Experimental description

- Equipment: BTS GaitEliteClinic 2.9.2
- Used protocol: Davis
- Experimental set-up applied: None

Course "Motion Analysis and clinics: why to set up a Motion Analysis Lab ?"
 - *Clinical cases presentation* - TRAMA Project – January 14 – 17th 2008 

 **Clinical case presentation**  

Main conclusions:

1. The syndrome Morquio is a skeletal dysplasia that produce rhizomelic shortening of limbs.
2. The knee are prone to valgus deformities.
3. Early knee osteotomy and transposition of medial collateral ligament.
4. Results are uncertain

Course "Motion Analysis and clinics: why to set up a Motion Analysis Lab ?"
 - *Clinical cases presentation* - TRAMA Project – January 14 – 17th 2008 